

Male Reproductive Tract: Penis Endocrinology

Jing-yao Liang, Kuo General Hospital, Tainan, Taiwan; Chang Jung Christian University, Tainan, Taiwan

Hong-Chiang Chang, National Taiwan University, Taipei, Taiwan

Geng-Long Hsu, Hsu's Andrology and National Taiwan University, Taipei, Taiwan

© 2018 Elsevier Inc. All rights reserved.

Introduction to Androgens and Other Hormones That Affect the Penis	2
How Hormones Affect the Penis in Different Stages of Life	3
Prenatal Stage	3
Early Infancy	3
Before Puberty	3
Puberty	4
Reproductive Stage	4
Aging Stage	4
Diagnosis and Management of Endocrine-Related Penile Conditions	4
Late-Onset Hypogonadism (LOH)	4
Delayed Puberty	4
Congenital Adrenal Hyperplasia (CAH)	5
Growth Hormone Deficiency and Related Conditions	6
Adrenal Virilism or Adrenogenital Syndrome	6
Congenital 5 α -Reductase Deficiency	6
Further Reading	6

Glossary

ACTH (adrenocorticotrophic hormone) Also known as corticotropin, is a polypeptide tropic hormone produced and secreted by the anterior pituitary gland.

Adrenarche It is a term to describe an early stage of sexual maturation in many higher primates that in human occurs at some 10–11 years of age. In boys, the principal physical consequences of adrenarche are especially pubic hair growth, change of sweat composition that produces adult body odor, increasing oiliness of the skin and hair and mild acne may occur.

Aldosterone The main mineralocorticoid hormone is a steroid hormone produced by the zona glomerulosa of the adrenal cortex in the adrenal gland.

Androgen A category of natural or synthetic compounds, mostly steroid hormones that stimulate or control the development and maintenance of male characteristics.

Androgen receptors It is a type of receptor in the nucleus of a cell, which is activated by binding androgenic hormones such as testosterone and dihydrotestosterone in the cytoplasm and then conveyed into the nucleus. It plays mainly as a DNA-binding transcription factor that regulates gene expression.

CAH (congenital adrenal hyperplasia) Any of several autosomal recessive diseases resulting from mutations of genes for enzymes mediating the biochemical steps of production of mineralocorticoids, glucocorticoids or sex steroids from cholesterol by the adrenal glands (steroidogenesis).

DHEA (dehydroepiandrosterone) The primary precursor of natural androgens and estrogens. It is also named as dehydroisoandrosterone or dehydroandrosterone.

DHT (dihydrotestosterone) A metabolite of testosterone, and a more potent androgen than testosterone in terms of affinity toward androgen receptors.

Erectile dysfunction The inability to either attain or maintain a rigid erection for satisfactory coitus.

GH (growth hormone) It is also known as somatotropin, a peptide hormone that stimulates growth, cell reproduction, and cell regeneration in humans and other animals.

IGF-1 (insulin-like growth factor 1) A hormone similar in molecular structure to insulin. It plays an important role in childhood growth and continues to have anabolic effects in adults.

Pubarche It is a term to describe the first appearance of pubic hair in a child. It usually results from rising levels of androgens from the testes or adrenal glands and is one of the prominent physical changes of puberty.

SHBG (sex hormone-binding globulin) or sex steroid binding globulin (SSBG) A glycoprotein that binds to the two sex hormones: androgen and estrogen.

SRY (sex-determining region Y protein) A DNA-binding protein (also known as gene-regulatory protein/transcription factor) encoded by the SRY gene that is responsible for the initiation of male sex determination in humans.

Testosterone The primary male sex hormone, an anabolic steroid, which plays the key role in the development of male reproductive tissues such as prostate, testicles and promoting secondary sexual characteristics such as hair growth and increasing muscle and bone mass.

Introduction to Androgens and Other Hormones That Affect the Penis

Androgens refer to a number of natural or synthetic compounds, mostly steroid hormones that stimulate or control the development and maintenance of male characteristics in vertebrates. They exert their action through binding to and activation of the androgen receptor which is a ligand-dependent nuclear transcription factor and a member of the steroid hormone nuclear receptor family. Given its widespread scattering in many tissues and specific cells, the androgen receptor has a diverse range of biological actions including pivotal roles in the development and maintenance of the cardiovascular, immune, neural, musculoskeletal, hemopoietic and reproductive systems.

Dehydroepiandrosterone (DHEA) is synthesized from cholesterol (Fig. 1). Although it functions as an endogenous precursor to more potent androgens such as testosterone and dihydrotestosterone (DHT), DHEA has been found to possess some degree of androgenic activity in its own right, acting as a low affinity ($K_i = 1 \mu\text{M}$), weak partial agonist of the androgen receptor. DHEA and DHEA-S, its sulfate metabolite, also act as a neurosteroid and neurotrophin. Although a relatively weak androgen, DHEA is responsible for the androgenic effects of adrenarche, such as early pubic and axillary hair growth, adult-type body odor, increased oiliness of hair and skin, and mild acne. DHEA is also used orally as a medication and dietary supplement, to restore or increase DHEA and DHEA-S levels.

Testosterone is the primary and most well-known androgen. In men, testosterone plays a key role in the development of male reproductive tissues such as the testis and prostate, as well as promoting secondary sexual characteristics such as increased muscle and bone mass, and the growth of body hair. In addition, testosterone is involved in health and well-being, and the prevention of osteoporosis. Testosterone is biosynthesized in several steps from cholesterol and is converted in the liver to inactive metabolites. It is secreted primarily by the testicles of males and, to a lesser extent, the ovaries of females. Small amounts are also secreted by the adrenal glands. Testosterone is also an anabolic steroid, which is related to growth of muscle mass and strength, increased bone density and strength, and stimulation of linear growth and bone maturation.

Testosterone levels are at their highest during adolescence and early adulthood. The first physical signs of testosterone, or androgens, in the body are apparent during puberty. A boy's voice changes, his shoulders broaden, and his facial structure becomes more masculine. But as men get older, their testosterone levels decline about 1% per year after age 30 (Table 1).

Dihydrotestosterone (DHT), or 5α -dihydrotestosterone (5α -DHT), is an endogenous androgen. The enzyme 5α -reductase catalyzes the formation of DHT from testosterone in certain tissues including the prostate gland, seminal vesicles, epididymides, skin, hair follicles, liver, and brain. Relative to testosterone, DHT is considerably more potent as an agonist of the androgen receptor (AR). During male embryogenesis DHT has an essential role in the formation of the male external genitalia, while in the adult male DHT acts as the primary androgen in the prostate gland, seminal vesicles, skin, and hair follicles. It is, therefore, notorious for the prostate hyperplasia which, in turn, causes urinary obstruction in geriatric males.

Growth hormone (GH), also known as somatotropin, is a peptide hormone that stimulates growth, cell reproduction, and cell regeneration in humans and other animals. After its synthesis in the anterior pituitary gland, GH is released into the blood stream and then stimulates the liver to produce insulin-like growth factor-1 (IGF-1). IGF-1 then stimulates systemic body growth and has

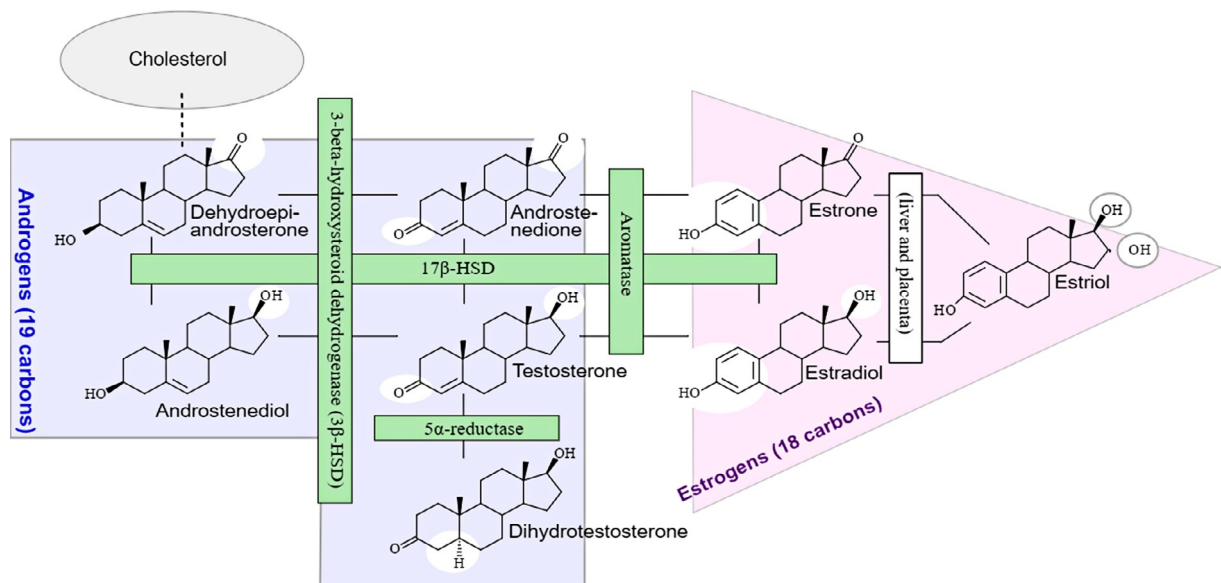


Fig. 1 Illustrative algorithms in human androgen production. Endogenous production of androgens and estrogens from the cholesterol which is the precursor. Originally from Häggström M, Richfield D (2014). "Diagram of the pathways of human steroidogenesis". WikiJournal of Medicine 1 (1). <https://doi.org/10.15347/wjm/2014.005>. ISSN 20024436.

Table 1 Demographic distribution of testosterone level in human

<i>Male</i>		<i>Female</i>	
<i>Age</i>	<i>T level (ng/dL)</i>	<i>Age</i>	<i>T level (ng/dL)</i>
0–5 months	75–400	0–5 months	20–80
6 months to 9 years	<7–20	6 months to 9 years	<7–20
10–11 years	<7–130	10–11 years	<7–44
12–13 years	<7–800	12–16 years	<7–75
14 years	<7–1200	17–18 years	20–75
15–16 years	100–1200	19+ years	8–60
17–18 years	300–1200		
19+ years	240–950		
Average adult male	270–1070	Average adult female	15–70

30+ years – 1% per year.

This chart breaks down the normal ranges of testosterone by age and gender, according to the Mayo Clinic.

growth-promoting effects on almost every cell in the body, especially skeletal muscle, cartilage, bone, liver, kidney, nerves, skin, hematopoietic cell, and lungs. An animal model showed that IGF-1 promotes proliferation and migration of cavernous smooth muscle cells. IGF-1 also stimulated vascular endothelial growth factor (VEGF) secretion from cavernous smooth muscle cells. Some clinics attempt to induce a penile enlargement by injecting recombinant human GH or IGF-1 into the corpus cavernosum, but there is no solid evidence supporting such practice.

Aldosterone is a steroid hormone produced by the zona glomerulosa of the adrenal cortex in the adrenal gland. It is essential for sodium conservation in the kidney, salivary glands, sweat glands, and colon. It plays a central role in the regulation of the plasma sodium (Na^+), the extracellular potassium (K^+) and arterial blood pressure. An in-vitro study on isolated human penile corpus cavernosal tissue showed that aldosterone has no direct contractile action or a relaxant action on human penile cavernous tissue, but acts to significantly enhance the noradrenaline-induced contraction. The effect on the noradrenaline-induced contraction is probably caused by aldosterone enhancing the affinity of the alpha-receptors for noradrenaline in isolated human penile corpus cavernosal tissue. The study suggested that aldosterone acts to enhance contraction of corpus cavernosal tissue, and is one of the restraining factors for human penile erection.

How Hormones Affect the Penis in Different Stages of Life

Prenatal Stage

In the human being, sexual differentiation is the process of developing observable traits difference on reproduction tracts between males and females. This includes the development of different genitalia and the internal genital tracts, breasts, body hair, and plays a role in gender identification. At an early stage in embryonic development, both sexes possess equivalent internal structures. These are the mesonephric ducts and paramesonephric ducts. As females have two X chromosomes, and males have one Y chromosome in addition to an X chromosome. The presence of the SRY gene on the Y chromosome causes the development of the testes in males, and the subsequent release of hormones which cause the paramesonephric ducts to regress.

By 7 weeks, a fetus has a genital tubercle, urogenital groove and sinus, and labioscrotal folds. Males become externally distinct between 8 and 12 weeks, as androgens enlarge the phallus and cause the urogenital groove and sinus to fuse in the midline, producing an unambiguous penis with a phallic urethra, and a thinned, rugated scrotum. In this stage, the role of testosterone is far smaller than that of dihydrotestosterone (DHT), and the latter will differentiate the remaining male characteristics. This reminds us that DHT plays so important role that the external genitalia can form normally and so does the prostate hyperplasia at males' early and late life respectively.

Early Infancy

In the first weeks of life for male infants, testosterone levels rise. The levels remain in a pubertal range for a few months but usually reach the barely detectable levels of childhood by 4–6 months of age. However, in this stage, no significant changes have been identified in other parts of the body.

Before Puberty

Before puberty effects of rising androgen levels occur in both boys and girls. These include adult-type body odor, increased oiliness of skin and hair, acne, the appearance of pubic hair (i.e., pubarche), axillary hair (armpit hair), growth spurt, accelerated bone

maturation, and facial hair. Erection of the penis is common for a prepubertal boy, but not until puberty does an “adult type” penis growth occur.

Puberty

Pubertal effect is commonly termed pubarche which begins to occur when androgen has been higher than normal adult female levels for months or years. In males, these are usual late pubertal effects and occur in women after prolonged periods of heightened levels of free testosterone in the blood. The effects include lots of events such as growth of spermatogenic tissue in testicles, male fertility, penis enlargement, increased libido and frequency of erection, remodeling of facial bone contours in conjunction with human growth hormone, completion of bone maturation and termination of growth, increased muscle strength and mass, shoulders become broader, rib cage expands, deepening of voice, growth of the Adam’s apple, enlargement of sebaceous glands, and altered body hair growth such as pubic hair, facial hair, chest hair, periareolar hair, perianal hair, and armpit hair etc.

According to the National Center for Health Statistics, the upper 95th percentile in the United States for onset age of puberty for boys is 14 (an increase in testicular size being the first sign).

Reproductive Stage

Progressive genital enlargement lasts into the third decade of life and is the result of increasing testosterone production from the testes and androgens from the adrenals. The period is characterized by an increase in the size of the penis, erections, sexual hair development, increase in muscle mass, acne, seborrhea, and a decrease in body fat.

Aging Stage

Testosterone levels reach a peak level around the third or fourth decade of life, then gradually reduce as men age. This effect is sometimes referred to as andropause or late-onset hypogonadism (LOH). Low testosterone levels can cause changes in sexual function, including reduced sexual desire, or low libido, fewer spontaneous erections, erectile dysfunction; infertility, and shrinkage of a penis. LOH is also associated with emotional changes, such as low self-confidence or lack of motivation; and physical changes, like increased body fat, reduced muscle bulk and strength, and decreased bone density.

Diagnosis and Management of Endocrine-Related Penile Conditions

Late-Onset Hypogonadism (LOH)

LOH is a clinical and biochemical syndrome associated with advancing age and characterized by typical symptoms mentioned in the previous paragraph, and most importantly, confirmed by the evidence of a low serum testosterone level. This testosterone reduction and associated symptom complex have been variously referred to as andropause, thereafter, terms of ADAM (androgen deficiency in the aging male), and PADAM (partial androgen deficiency in the aging male) are introduced.

There is a circadian variation in serum total testosterone. The blood sample should be obtained in the morning for an accurate reading.

As a man ages, the penis tends to undergo an actual reduction in size. The reduction—in both length and thickness—typically isn’t dramatic but may be noticeable. If a man’s erect penis is 6 in. long when he is in his 30s, it might be 5 or 5-and-a-half inches when he reaches his 60s or 70s. Atherosclerosis and fibrosis of corpus cavernosa are likely two major causes of penile shrinkage (Fig. 2). Albeit this phenomenon is not beyond controversy, it is always complained by a male whose age exceed 60 years suffers from gradual onset of penile dysmorphology associated with erectile dysfunction.

There is a strong association among age, testosterone deficiency, cavernosal fibrosis, and erectile dysfunction. Age, testosterone deficiency and cavernosal fibrosis are potentially correctable factors of cavernosal fibrosis and organic erectile dysfunction. Testosterone replacement therapy (TRT) alone or in association with phosphodiesterase-5 (PDE5) inhibitors, may lower the risk of cavernosal fibrosis or decrease the severity the fibrosis in patients with erectile dysfunction. It may resort to penile venous stripping and tunicular patching reconstruction if the disease fails to be free from deterioration chronologically.

Oral testosterone supplement, transdermal delivery, and injections are available routes of TRT. Only symptomatic subjects with documented evidence of low serum testosterone levels should consider having TRT, and the patient should be well informed about benefits, goals, and precautions of TRT. During replacement therapy, key parameters including testosterone, hematocrit, hemoglobin, prostatic specific antigen (PSA), blood pressure and liver function profile should be monitored.

Delayed Puberty

Delayed puberty in boys is defined clinically by the absence or incomplete development of secondary sexual characteristics by an age at which 95% of boys have initiated sexual maturation.

Constitutional growth delay (CGD) is the most common cause of short stature and pubertal delay. Other boys with delayed puberty usually result from hypogonadism (inadequate gonadal steroid secretion) which, in turn, is most often caused by a

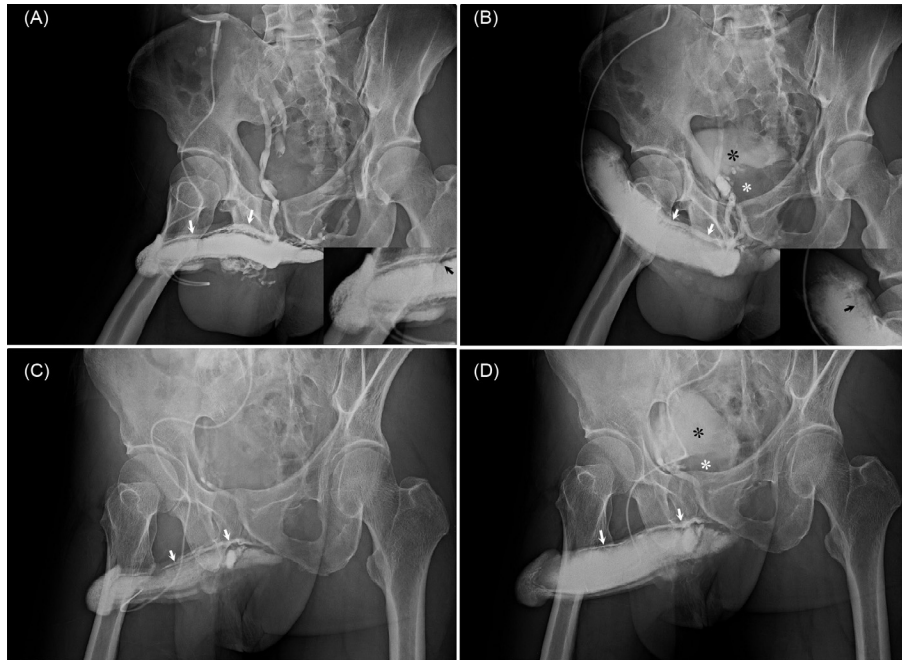


Fig. 2 Caverosographic evidence of tunical fibrosis in geriatric males? (A) In a 65-year-old man, the plain caverosogram (30° oblique views) was obtained when 20 mL diluted iohexol solution was injected into the corpora cavernosa via a no. 19 scalp needle. The deep dorsal vein (*white arrows*) was well demonstrated although the cavernosal veins were masked. Note that the radiolucent area (*black arrow*, inserted) was noted along the dorsal aspect of the distal corpora cavernosa. (B) An early phase of the pharmaco-caverosograms was made 15 min after the 20 µg prostaglandin E1 was injected intra-cavernously via the same scalp needle. Again the deep dorsal vein (*white arrows*) was well shown despite the penis was in a rigid erection. No smooth lineation was noted along the distal tunica albuginea (*black arrow*, inserted) resulting from peripheral sinusoids was tethered by fibrotic tunica. Does the dorsal contour fail to preserve lineation resulting from tunical fibrosis? Note the urinary (*black asterisk*) and the enlarged prostate gland (*white asterisk*) which occupies the bladder base. (C) In a 67-year-old man, the plain caverosogram (30° oblique views) was obtained when 20 mL diluted iohexol solution was injected into the corpora cavernosa via a no. 19 scalp needle. The deep dorsal vein (*white arrows*) was well noted although the cavernosal veins were masked. Note that the lineation of the dorsal aspect cannot be obvious. (D) Again an early phase of the pharmaco-caverosograms was undertaken 15 min after the 20 µg prostaglandin E1 was injected intra-cavernously via the same scalp needle. The deep dorsal vein (*white arrows*) was well shown. The contour of the dorsal tunica was not lineated resulting from peripheral sinusoids was tethered by fibrotic tunica. Does the dorsal contour fail to preserve lineation resulting from tunical fibrosis? Note the urinary (*black asterisk*) and the enlarged prostate gland (*white asterisk*) which occupies the bladder base.

defective gonadotropin secretion from the anterior pituitary, due to defective production of gonadotropin-releasing hormone (GnRH) from the hypothalamus.

High serum concentrations of LH and FSH are associated with various causes of gonadal disease, called primary hypogonadism and/or defects in their receptors on the membrane of the gonadal cells. Low or normal serum LH and FSH concentrations are associated with diminished GnRH-induced gonadotropin secretion, called secondary hypogonadism. This defect can be because of hypothalamic dysfunction (either anatomic or functional), hypopituitarism, hypothyroidism, or hyperprolactinemia.

Hormone therapy is reserved for patients with confirmed organic gonadotrophin deficiency (hypogonadotrophic hypogonadism), for those with a gonadal abnormality (e.g., Turner's syndrome, Klinefelter's syndrome), and for those with constitutional delay who have an abnormal psychosocial adjustment. Typically, those with constitutional delay require only a short course of intramuscular testosterone to induce puberty.

Patients with organic delay require early diagnosis and treatment to achieve normal development and optimal height and avoid issues of psychosocial adjustment with peers.

Congenital Adrenal Hyperplasia (CAH)

CAH refer to any of several autosomal recessive diseases resulting from mutations of genes for enzymes mediating the biochemical steps of production of mineralocorticoids, glucocorticoids or sex steroids from cholesterol by the adrenal glands (steroidogenesis).

There are six major forms of CAH, each caused by a mutation of one of the six enzymes required for the biosynthesis of cortisol. In each of these forms, the decrease in cortisol secretion results in a decrease in negative feedback at the level of the hypothalamus-pituitary. The resulting increase in adrenocorticotrophic hormone (ACTH) vs. corticotropin-releasing hormone (CRH) output attempts to return the cortisol secretion to normal if the mutation permits some degree of enzymatic activity. At the same time, the increased ACTH secretion results in a markedly elevated production of the cortisol precursors before the mutant block.

Some female infants with classic CAH have ambiguous genitalia due to exposure to high concentrations of androgens in utero. CAH due to 21-hydroxylase deficiency is the most common cause of ambiguous genitalia in genotypically normal female infants (46XX). They may be raised as boys due to enlarged clitoris mimicking penises. Less severely affected females may present with early pubarche. Young women may present with symptoms of polycystic ovarian syndrome which manifests oligomenorrhea, polycystic ovaries and hirsutism.

Males with classic CAH generally have no signs of CAH at birth. Some may present with hyperpigmentation, due to co-secretion with melanocyte-stimulating hormone (MSH), and possible penile enlargement.

Growth Hormone Deficiency and Related Conditions

Congenital GH deficiency is associated with aberrant androgen physiology and micropenis. GH replacement therapy alone can result in a catch-up in phallic size in patients with micropenis secondary to isolated congenital GH deficiency.

While for cases with GHRH (growth hormone releasing hormone) receptor deficiency, the patients have a normal penis size before puberty, whereas micropenis is typical of GH deficiency and GH receptor deficiency. Severe GH deficiency is associated with small penis size with normal penile growth at adolescence or with testosterone treatment in childhood. This is also true of GH receptor deficiency.

Adrenal Virilism or Adrenogenital Syndrome

Adrenal virilism is a syndrome in which excessive adrenal androgens cause virilization, i.e. masculinization. Diagnosis is clinical and confirmed by elevated androgen levels with and without dexamethasone suppression; determining the cause may involve adrenal imaging. There may be functioning adrenal tumors resulting in masculinization of prepubertal children. In boys, it produces a pseudoprecocious puberty. Sexual hair develops and the penis is enlarged to adult size, with frequent erections.

Treatment depends on the cause whereby adrenalectomy, removal of the causation tumor, or oral glucocorticoids for non-tumor hyperplasia is a specific option.

Congenital 5 α -Reductase Deficiency

This is an autosomal recessive intersex condition caused by a mutation in the 5 α reductase type II gene. This genetic mutation can result in pseudohermaphroditism. The condition typically presents with underdeveloped male genitalia and prostate. Males with this condition are often raised as girls due to their lack of conspicuous male genitalia. At the onset of puberty, although still in lack of DHT, their testosterone levels elevate normally. Their musculature develops like that of other male adults. After puberty, men with this condition have a large deficiency of pubic and body hair and reportedly no incidence of androgenic alopecia (pattern hair loss), and no incidence of prostate cancer.

Further Reading

- Brawer MK (2004) Testosterone replacement in men with andropause: an overview. *Revista de Urología* 6(Suppl. 6): S9–S15.
- Carrillo A, et al. (2007) *Pediatric endocrinology*, 5th edn., vol. 2, pp. 365–384. Wiley-Blackwell. Chapter 15.
- Davey RA and Grossmann M (2016) Androgen receptor structure, function and biology: from bench to bedside. *Clinical Biochemist Reviews* 37(1): 3–15.
- Hsu GL, et al. (2007) Long-term result of an autologous venous grafting for penile morphological reconstruction. *Journal of Andrology* 28(1): 186–193.
- Hsu GL, Molodysky E, Liu SP, Chang HC, Hsieh CH, and Hsu CY (2013) Reconstructive surgery for idealizing penile shape and erectile functional restoration on patients with penile dysmorphism and erectile dysfunction. *Arab Journal of Urology* 11(4): 375–383.
- Hughes IA (2011) Minireview: sex differentiation. Available: <http://endo.endojournals.org/content/142/8/3281.full>.
- Iacono F (2012) Testosterone deficiency causes penile fibrosis and organic erectile dysfunction in aging men. Evaluating association among age, TDS and ED. *BMC Surgery* 12(Suppl. 1): S24.
- Levy JB and Husmann DA (1996) Micropenis secondary to growth hormone deficiency: does treatment with growth hormone alone result in adequate penile growth? *Journal of Urology* 156(1): 214–216.
- Liu X, Lin CS, Spencer EM, and Lue TF (2001) Insulin-like growth factor-I promotes proliferation and migration of cavernous smooth muscle cells. *Biochemical and Biophysical Research Communications* 280(5): 1307–1315.
- Muguruma H, et al. (2008) Effect of aldosterone on isolated human penile corpus cavernosum tissue. *BJU International* 102(4): 500–503. <https://doi.org/10.1111/j.1464-410X.2008.07536.x>.
- Pescovitz OH and Eugster EA (2004) *Pediatric endocrinology: mechanisms, manifestations, and management*, pp. 991–995. Totowa, NJ: Humana Press Inc.
- Playmate SR (1989) Circadian variation in testosterone, sex hormone binding globulin, and calculated non-sex hormone-binding globulin bound testosterone in healthy young and elderly men. *Journal of Andrology* 10(5): 366–377.
- Rosenbloom AL (2007) *Pediatric endocrinology*, 5th edn., vol. 2, p. 75. Informa healthcare USA, Inc. Chapter 3.
- Young HK and Kim JJ (2011) Testosterone replacement therapy for late-onset hypogonadism: current trends in Korea. *Asian Journal of Andrology* 13(4): 563–568.